



Summary Feedback

(Combined feedback broadcasted at multiple times this week)

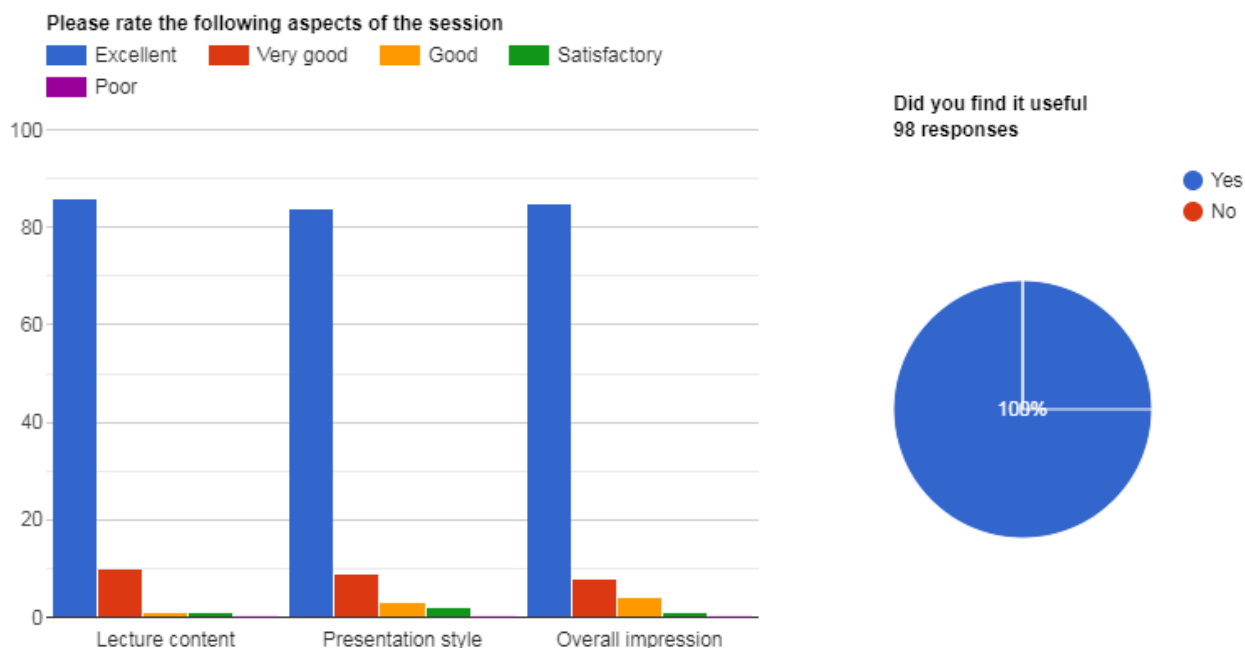
PRE-RECORDED: Basildon FRCR 2B 'A to Zee' Course 2020

Session 1/40

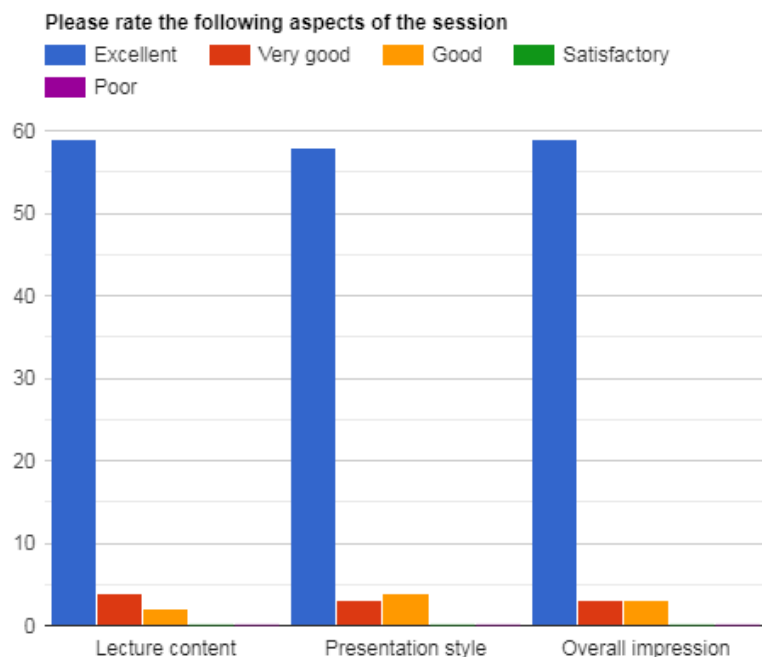
Chest X-Ray For FRCR Exam (Part-1)
(4th and 5th May 2024)
Lecturer: Thaj Rehman

Summary Points:

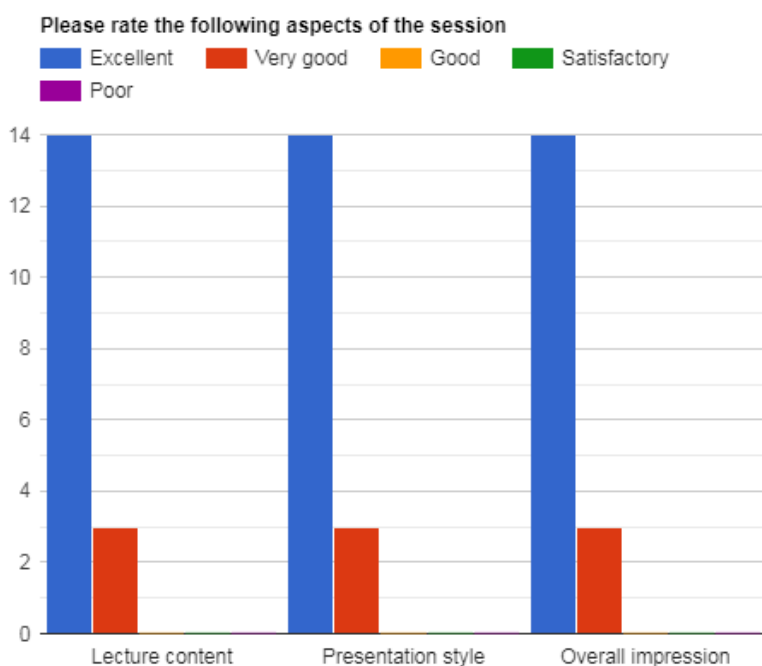
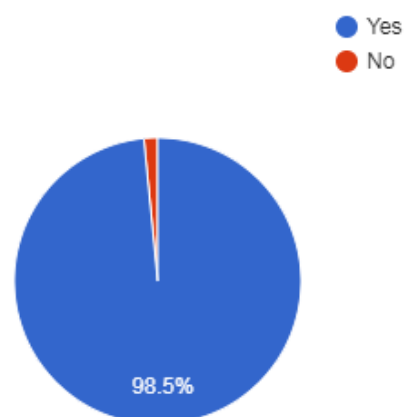
- Total Attendees: 515 from 37 Countries (Algeria, Bahrain, Bangladesh, Brunei, Dominica, Egypt, Ghana, Hong Kong, India, Indonesia, Iraq, Jordan, Kenya, Libya, Malaysia, Maldives, Mauritius, Myanmar, Nepal, Nigeria, Oman, Pakistan, Poland, Qatar, Saudi Arabia, Singapore, South Africa, Sri Lanka, Sudan, Swaziland, Türkiye, UAE, UK, Ukraine, Yemen, Zambia, Zimbabwe).
- Total duration: 3 hours (each session broadcasted thrice during the week)
- Total feedback received from 180 participants, from three different broadcasts



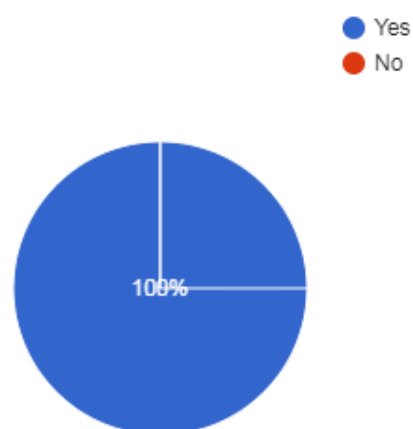
CHEST X-RAY FOR FRCR EXAM (Part-1)



Did you find it useful
65 responses



Did you find it useful
17 responses



Testimonials

- The break downs of the differentials for the lesions in mediastinum was most useful. He is really good with explanations and helping us understand these concepts (UK).
- I liked a large volume of exam focused chest X-ray pathologies with explanation of key findings and buzzwords for the 2B exam (UK).
- Covered a wide range of pathologies and lots of basics of CXR. Very useful for 2b revision (UK).
- Lot of good cases covered within a short time and quick explanation (India).
- Teacher's explanations are clear and understandable and also I can learn from candidate's reporting technique (Myanmar).

CHEST X-RAY FOR FRCR EXAM (Part-1)

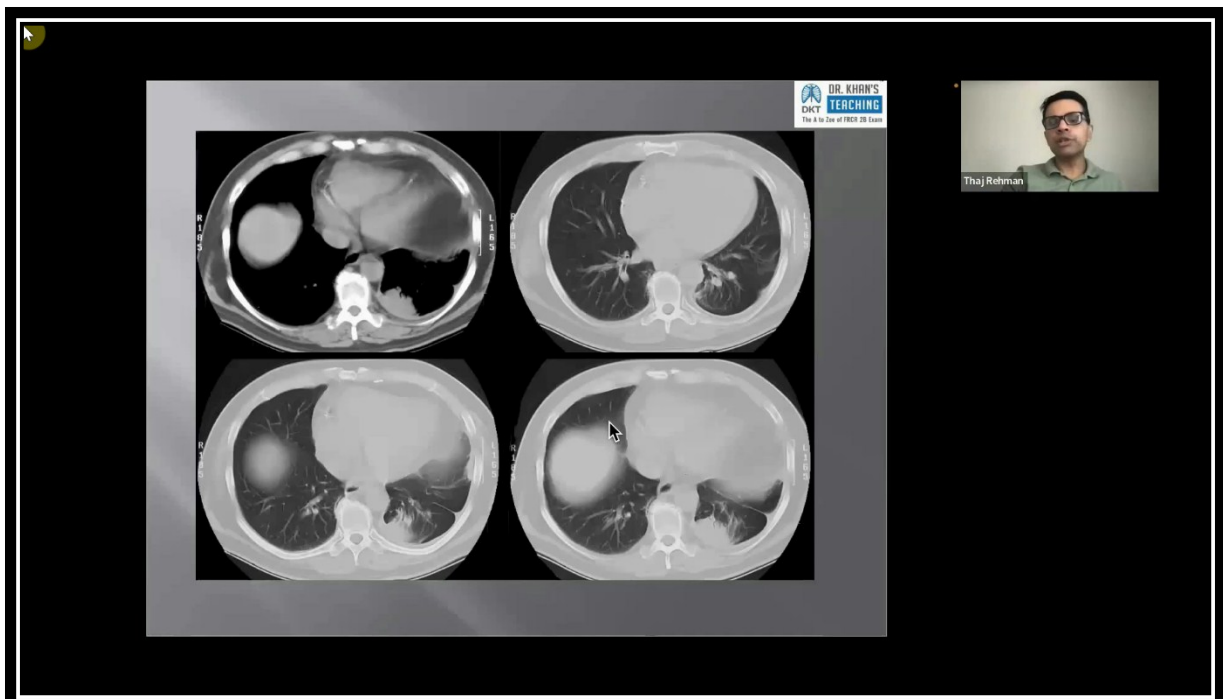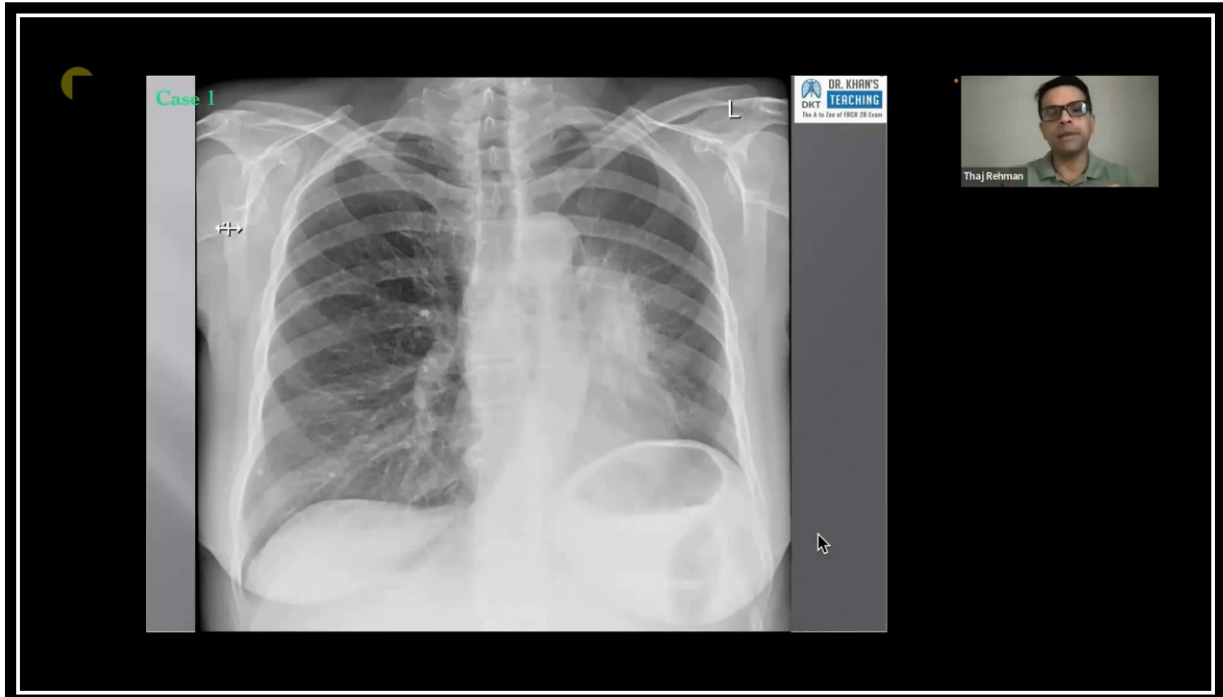
- The whole lecture content is excellent and very useful for examination point of view (India).
- Excellent and very useful 2B revision session on chest X-ray pathologies. I look forward to the next session! (UK).
- The examiner correcting the candidates and giving inputs like how to go about it in the exam was most valuable (India).
- I need to go over this lecture again. It's really needed (UK).
- Every X-ray was explained in details with all the findings and differentials was very valuable (Pakistan).
- The variety of cases helping to refresh memory on review areas and differentials were most useful (UK).
- It's really good that it's a mix of viva and didactics (UK).
- It helped me in to clear the mediastinum and lung mass difference (Pakistan).
- The differentials being discussed gives an understanding how to come to a conclusion was most useful (India).
- Excellent teaching as always reminding important and salient features on chest X-ray reporting (UK).
- Very good cases for rapid reports and good interpretation (UK).
- The candidates viva mode 'hot seat' style was most useful (Nigeria).
- Using correct description of the abnormality was most useful (Malaysia).
- Examples cases and explanation were most useful (UK).
- Differentiation of lung mass from the mediastinal mass and finding abnormalities in lateral x-ray were most useful (UK).
- Chest radiograph cases and approach of interpretation was most useful (UK).
- The approach to the cases and explanation of the thinking process was most valuable (UK).
- Detailed explanation of chest X-rays were most useful (Pakistan).
- Excellent classes and cases (India).
- I liked the exam oriented discussion and cases, with useful pointers (Malaysia).
- Excellent chest X-ray cases (Saudi Arabia).
- Classic exam cases were most useful, thank you (UAE).
- Approach to mediastinal mass and cervicothoracic sign were most useful (Zimbabwe).
- Useful not only for day to day practice but also for the exams (UK).
- Everything is great (Yemen).
- Woow (Egypt).
- Cases were wonderful (Pakistan).
- Case selection and calm detailed feedback was most useful (UK).
- Explanation of X-ray signs were most useful (Egypt).
- Interesting cases and very good teaching (Sri Lanka).
- How to interpret and express the thought processes were most useful (Malaysia).
- The CXRs that were shown and the explanation were most useful (UK).
- It was perfect (UAE).
- Visas plus lecture notes after the case were most useful (Zimbabwe).
- Different cases of same system and modality was useful (Saudi Arabia).
- Good teaching of basic signs in chest and how to differentiate between lesions (Pakistan).
- Explanation by the consultant was most useful and valuable (Pakistan).
- Varieties of CXR findings and the examiner feedback was most useful (Malaysia).
- Chapman's differentials approach was most useful (India).
- Valuable feedback. Excellent cases (UK).

CHEST X-RAY FOR FRCR EXAM (Part-1)

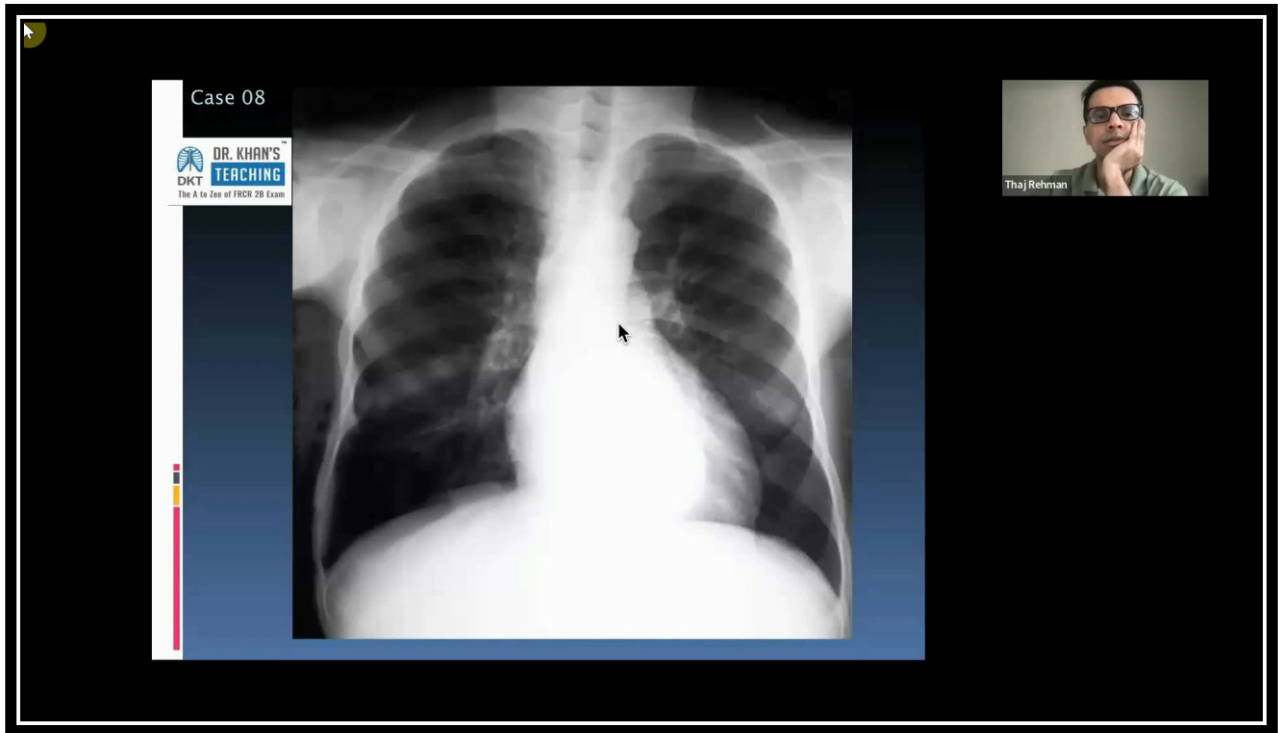
- The tips and finer points of reading a chest radiograph were most useful (Malaysia).
- Lots of cases and excellent explanation. Really valuable (UK).
- I liked the focused teaching points (UK).
- Amazing collection of cases (Iraq).
- Good fast pace (UK).
- Excellent teaching (UK).
- Nice selection of cases (India).
- I liked the knowledge, radiological signs and cases (Iraq).
- Very detailed explanations was most useful (UK).
- Best session (Pakistan).
- Excellent and nice lecture (India).
- Brilliant (Kuwait).
- Amazing and unique learning opportunity (UK).
- Great efforts (Pakistan).
- Very helpful (India).
- Very informative (India).
- Excellent cases and feedback (Algeria).
- Informative and excellent session (Myanmar).
- Very helpful for the day to day practice as well (UK).
- Excellent learning session (UK).
- Overall it is very good (India).
- Excellent and useful (Jordan).
- Good, thanks a lot (India).
- Excellent session (Pakistan).
- Wonderful. Thank you! (Malaysia).
- It was a very useful session (India).
- Real cases of chest radiographs were most useful (Pakistan).
- Great lecture (Yemen).
- Good cases (India).
- Great knowledge (Pakistan).
- Feedback was excellent (Kenya).
- Cases are very well oriented and well explained (Pakistan).
- Excellent cases and discussion (UK).
- Much informative (Pakistan).
- Cases selection and discussion was most useful (UAE).
- I liked the simplified and detail explanation of imaging (India).
- The lecturer is quite well skilled (UK).
- The way of teaching the basics of chest radiology was most valuable (Pakistan).
- I liked the various chest X-rays acute and chronic abnormalities and differentials (Pakistan).
- Excellent teaching (Malaysia).
- Very useful teaching session (Malaysia).
- Impressed (Pakistan).
- Very informative (Pakistan).
- Good. Informative (Malaysia).
- Fantastic (UK).
- A decent good presentation (Pakistan).
- A great teaching session (UK).

CHEST X-RAY FOR FRCR EXAM (Part-1)

- The explanation given by teacher was most useful and valuable (Pakistan).
- Overall nice covering all aspects of a common topic (Pakistan).
- Excellent teaching (Malaysia).
- Very useful teaching sessions. Thank you (Malaysia).
- Very good lecture (Pakistan).
- Excellent, short and sweet (Malaysia)
- The teacher was very kind and elaborative (Pakistan).
- Very useful (UK).
- Excellent counter questioning and cases (Pakistan).



CHEST X-RAY FOR FRCR EXAM (Part-1)



=====XX=====XX=====